

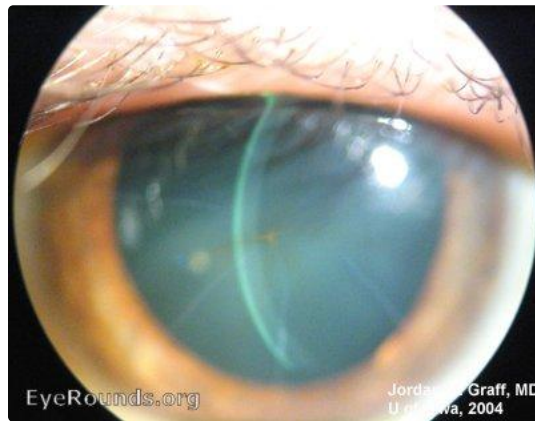
BRK (radial keratotomy) with tear star

Category(ies): Cornea

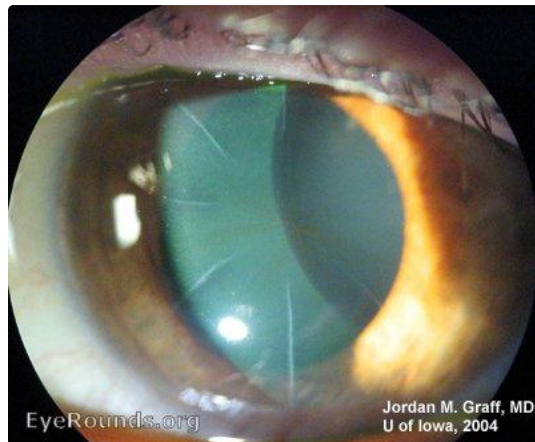
Contributor: [Jordan Graff, MD](#)



The familiar radial incision lines of RK are visible. Additionally, in this case, a characteristic star-shaped iron deposit has formed centrally. This is called a "tear star" and occurs in some patients with RK. This tear star has no effect on vision.



[Enlarge](#) [Download](#)



[Enlarge](#) [Download](#)

Image Permissions:



Address

University of Iowa
Roy J. and Lucille A. Carver College
of Medicine
Department of Ophthalmology and
Visual Sciences
200 Hawkins Drive
Iowa City, IA 52242

[Support Us](#)

Legal

Copyright © 2019 The University of
Iowa. All Rights Reserved
[Report an issue with this page](#)
[Web Privacy Policy](#) |
[Nondiscrimination Statement](#)

Related Links

[Cataract Surgery for Greenhorns](#)
[EyeTransillumination](#)
[Gonioscopy.org](#)
[Iowa Glaucoma Curriculum](#)
[Iowa Wet Lab](#)
[Patient Information](#)
[Stone Rounds](#)
[The Best Hits Bookshelf](#)

EyeRounds Social Media

Follow



Receive notification of new cases,
[sign up here](#)
[Contact Us](#)
[Submit a Suggestion](#)